



**PATIENT**

Kiwi Bakondi

**SPECIES**

Feline

**BREED**

DLH

**SEX**

Female Spayed

**AGE**

10.26.05

**WEIGHT**

10.79lbs

**INTERPRETED BY**

Maggie Machen Lamy,  
DVM, DACVIM  
(Cardiology)

**HOSPITAL NAME**

Cat Hospital at Towson

**REFERRING VET**

Dr. Slaughter

**INVOICE**

28692

**DATE**

2.1.23

**PRESENTING CLINICAL SIGNS**

- History: Elevated ProBNP.
- Pertinent abnormal PE/Chem/CBC/UA Results: Anemia, stage 2 CKD, decreased potassium, elevated ProBNP.
- Current medications: None listed.
- Sedation used: Not required to complete full diagnostic ultrasound.
- Pertinent previous ultrasound results: No previous.
- STAT: Not requested
- Imaging performed by: Andi Parkinson, BS, RDMS.

**ECHOCARDIOGRAM FINDINGS**

2D, m-mode, color flow and doppler imaging is available. The left ventricular wall is borderline in dimension with regions of irregularity. There is a diffusely hyperechoic endocardium consistent with fibrosis. The endocardium also appears mildly remodeled. Mild papillary muscle hypertrophy. The left atrium is normal. The mitral valve is normal in structure and mobility. No MR. The right atrium is normal in size. The right ventricle appears normal. No TR. Blood flow through the LVOT is normal, laminar flow. Blood flow through the RVOT is normal in velocity. No AI/PI. No obvious cardiac tumors identified. No effusions.

**CARDIAC CHART**

FELINE CARDIAC PARAMETERS	BODY WEIGHT (kg)	HR (BPM)	IVSd (cm) (Moise, Pipers)	LVIDd (cm) (Moise, Pipers)	LWVd (cm) (Moise, Pipers)	FS (%)	EF (%)
NORMAL PARAMETER	-----	150-240	3.5-0.55	<2 (mean 1.5)	3.5-0.55	35-67	80-100
PATIENT	4.9	NM	0.56	1.0	0.54	39	74
FELINE CARDIAC PARAMETERS	LA/AO (Boon)	LA/AO HEART BASE (Swe) (Abbott)	LA 2D short axis Base view (cm) (Abbott)		LVOT VEL (m/s)	RVOT VEL (m/s)	E max (m/s)
NORMAL	<1.5	<1.3	<1.2		<1.6	<1.3	<0.9
PATIENT	NM	1.2	1.1		1.4	0.96	NM

Adapted from June Boon, Veterinary Echocardiography, 1998  
Abbott J & MacLean H JVIM 2006;20: 111-119, Moise et al. Am J Vet Res 47:1476, 1986. Pipers et al. Am J Vet Res 40:882, 1979.

### INTERPRETATION OF THE FINDINGS & FURTHER RECOMMENDATIONS

Overtly normal geriatric cardiac structure and function. There is fibrosis of the left ventricular wall and high normal LV wall dimensions which may be indicative of early cardiac disease or may simply represent a normal variant. The fibrosis alone is theoretically enough to explain an elevated BNP, however other causes of elevation such as **hypertension or CKD** should be ruled out. Regardless, the LA remains normal which would indicate clinical stability. Serial echocardiography will be necessary to determine progression. A screening BP and T4 are recommended every 6 months as possible contributing factors.

Anesthetic risk is mild, however any cat with fibrosis and diastolic dysfunction will be at risk for IV fluid overload. Careful monitoring of breathing rates during and after administration is advised.

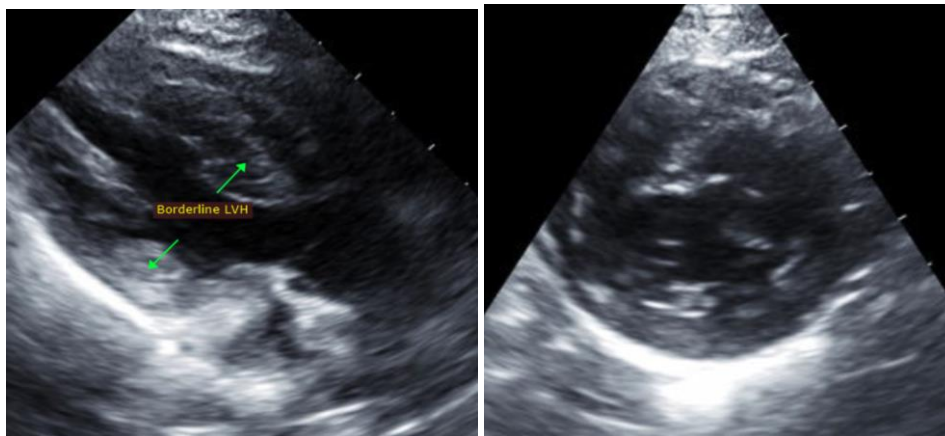
No cardiac specific medications are indicated. Monitor for any development of clinical signs, including labored breathing or signs of a blood clot (paralysis, neurologic change).

### PLAN

Baseline BP and T4 are recommended every 6 months.

A recheck echocardiogram is recommended in 6-12 months to screen for any evidence of progression.

### IMAGES



The information and recommendations provided are based on the images presented by the referring veterinarian. No evaluation can be communicated regarding pathology that was not visible in the image/video clips provided.

Thank you for this referral. This report was generated using transcription software, and minor dictation errors may be present. If the clinical or image interpretation does not parallel your findings or if I can be of any further assistance please contact me.

**Maggie Machen Lamy, DVM**  
Diplomate of the American College of Veterinary Internal Medicine (Cardiology)  
info@sonopath.com